

# AIRLIFT™

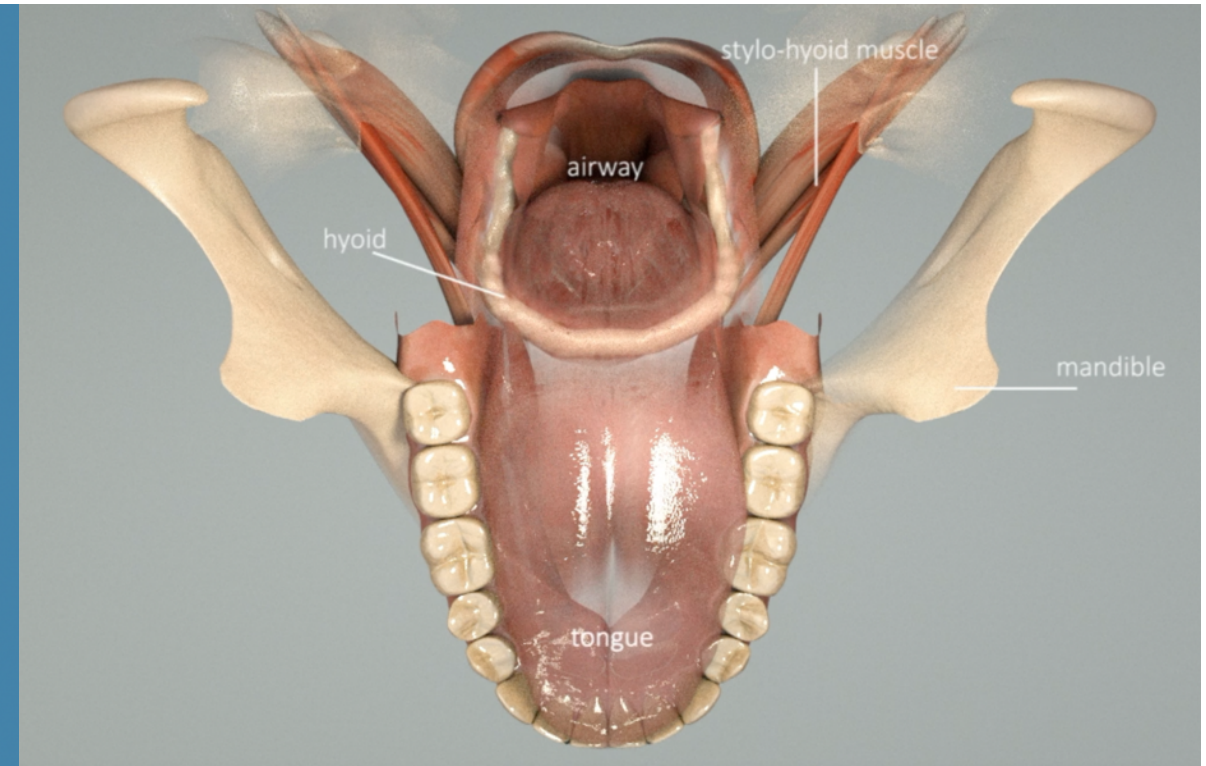
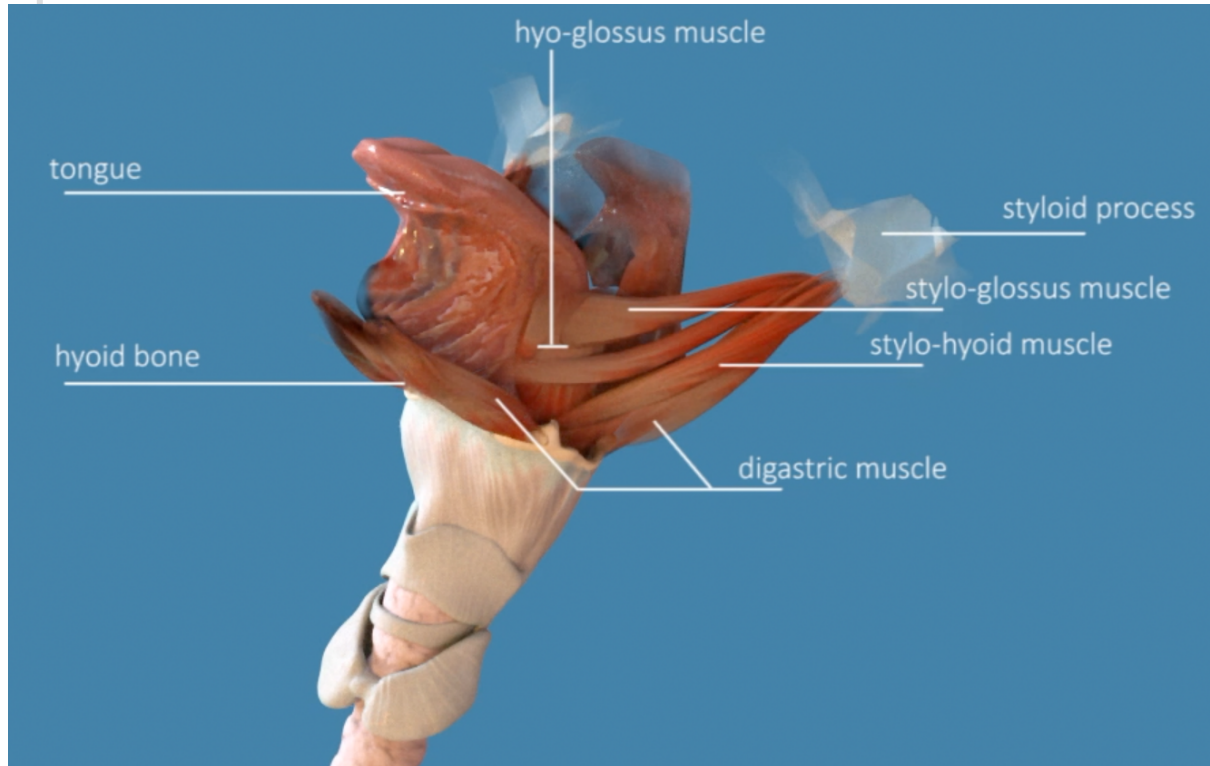
---

Fluoroscopy before and after advancement

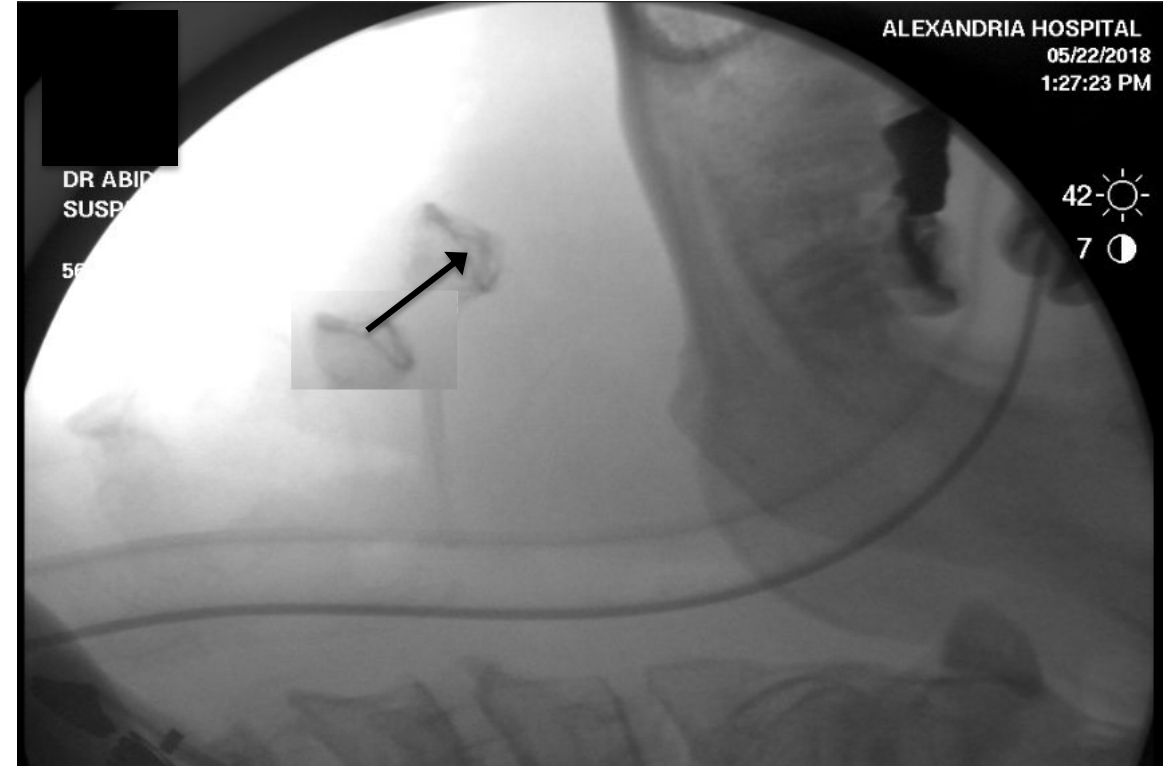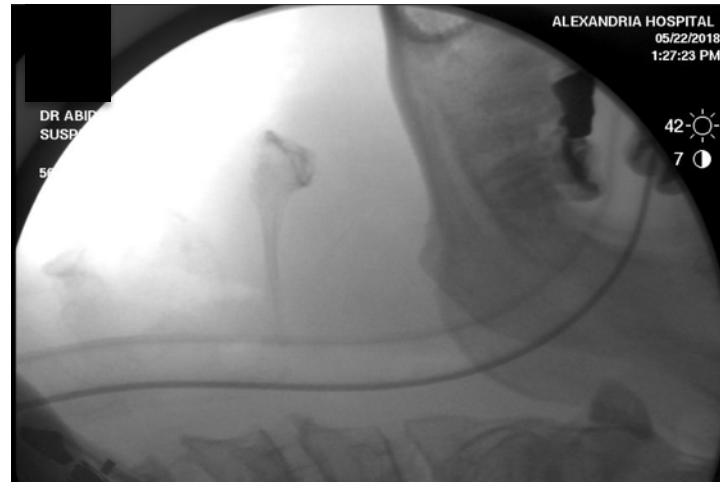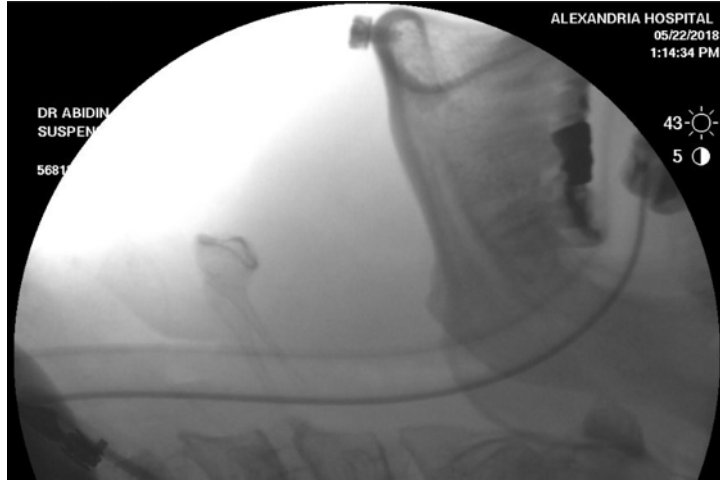
Dr. Michael Abidin, Alexandria, VA

---

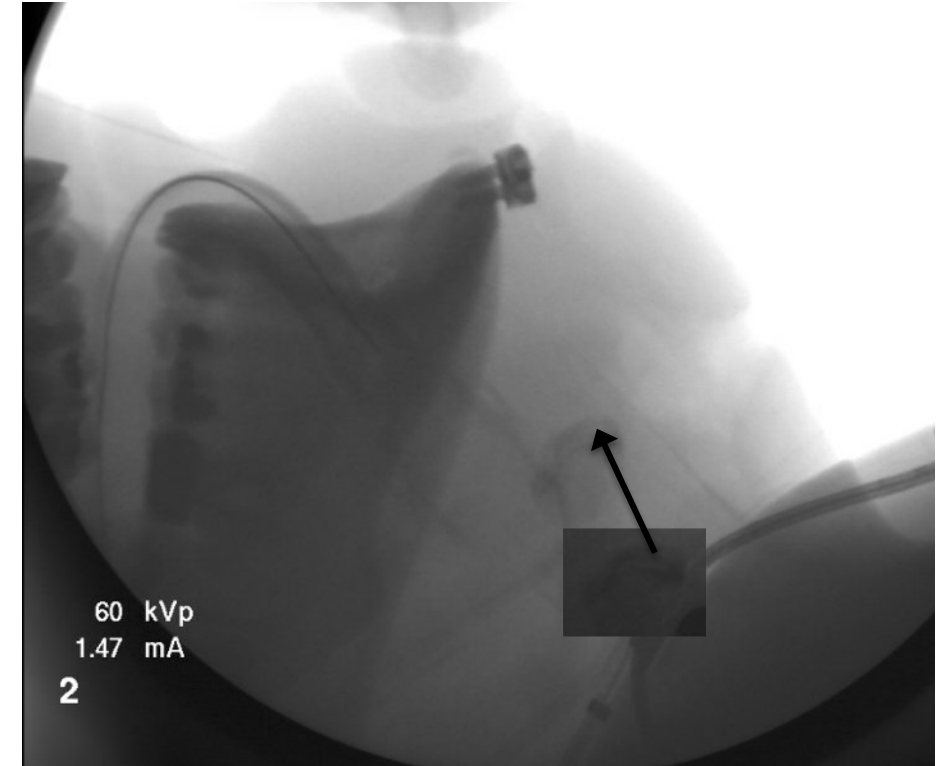
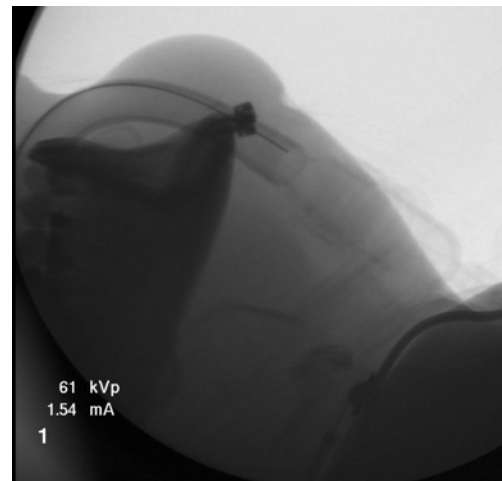
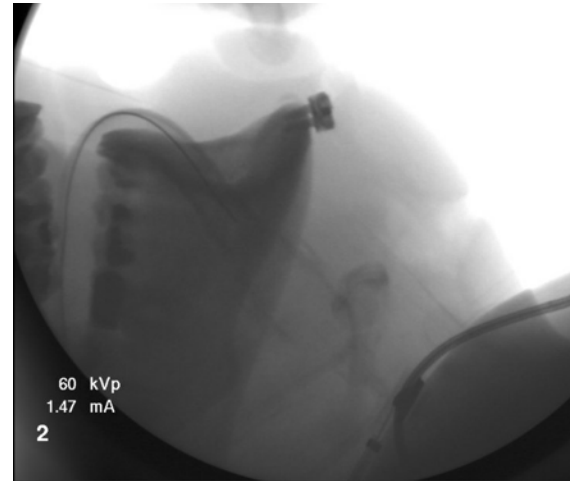
# The Hyoid: a Well-Connected Airway Stabilizer



## Patient #1

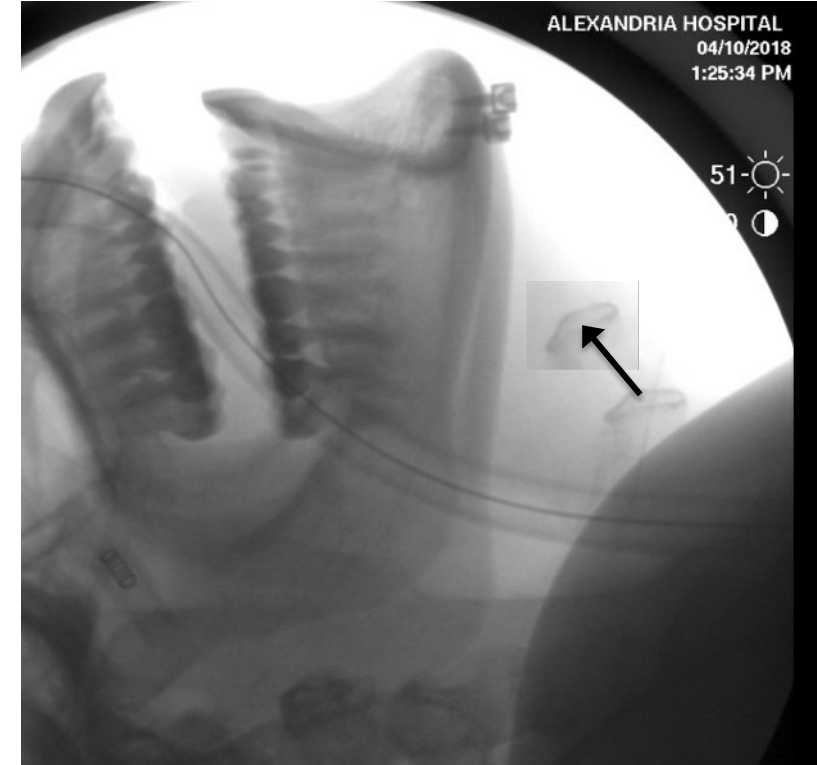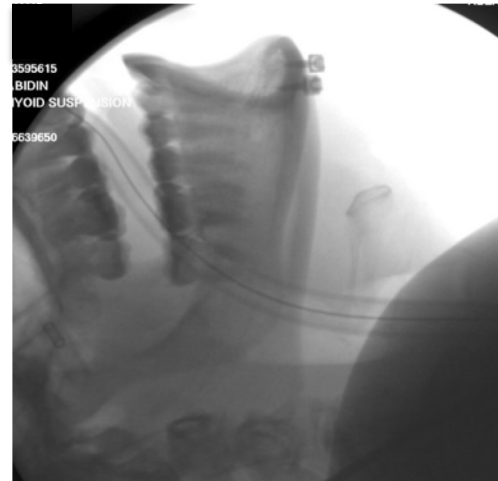

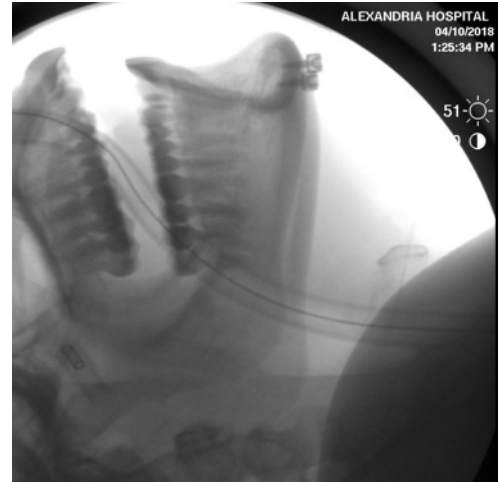
## Patient #2

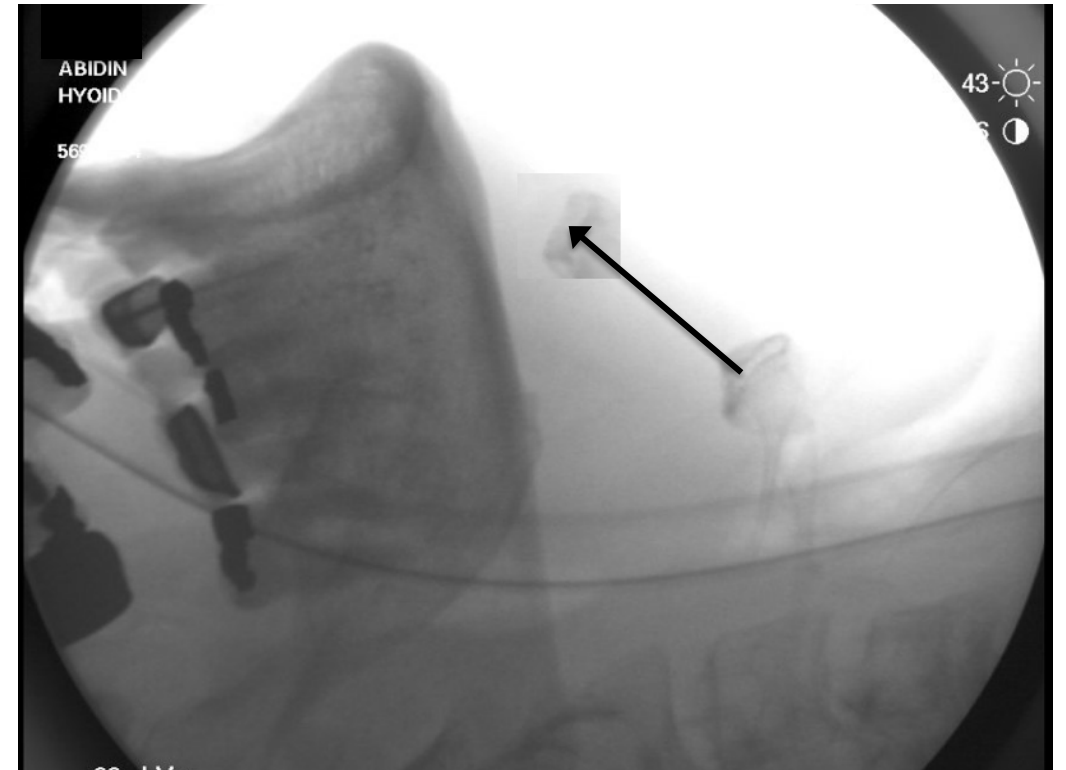
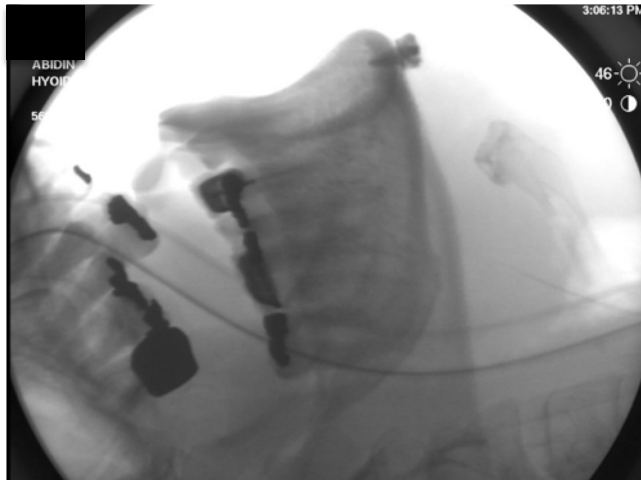
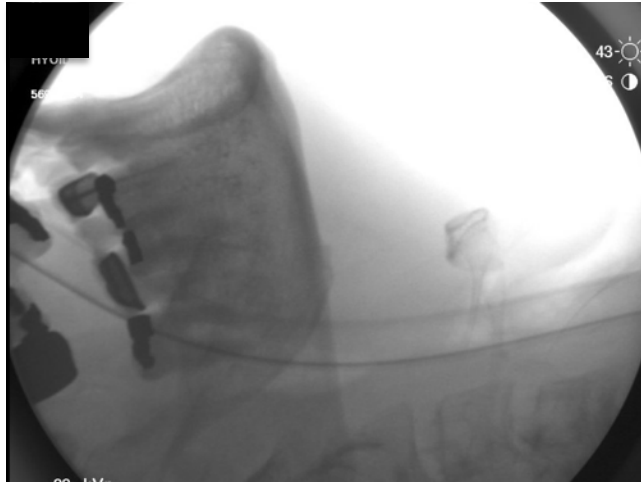




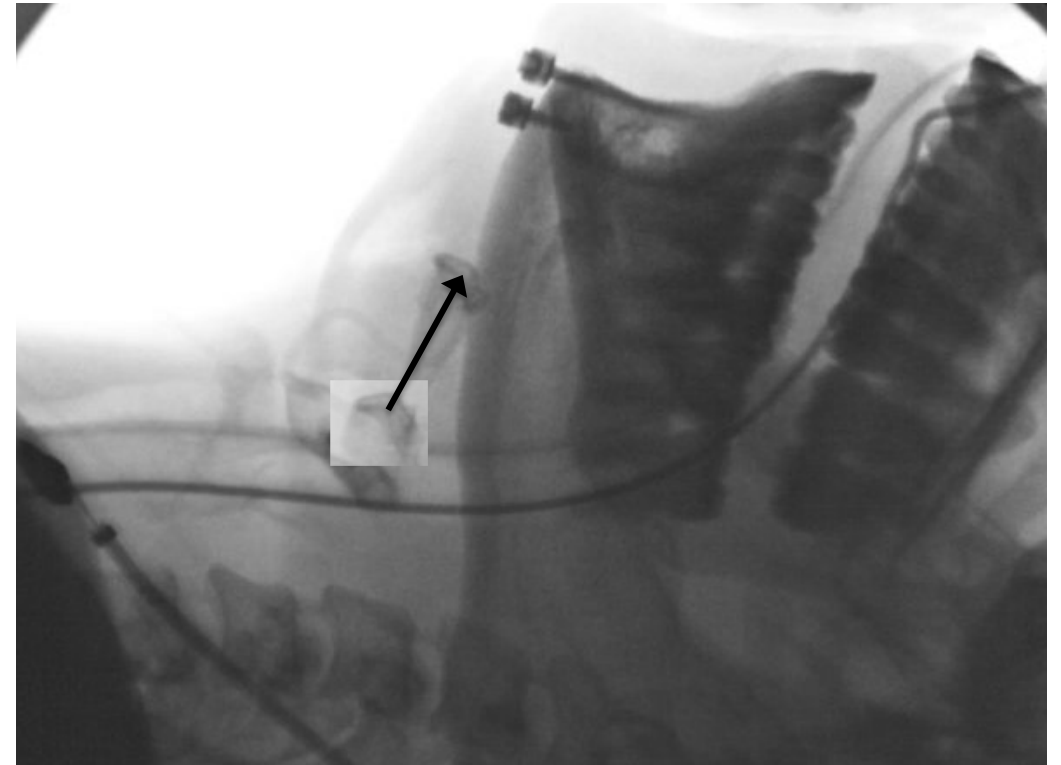
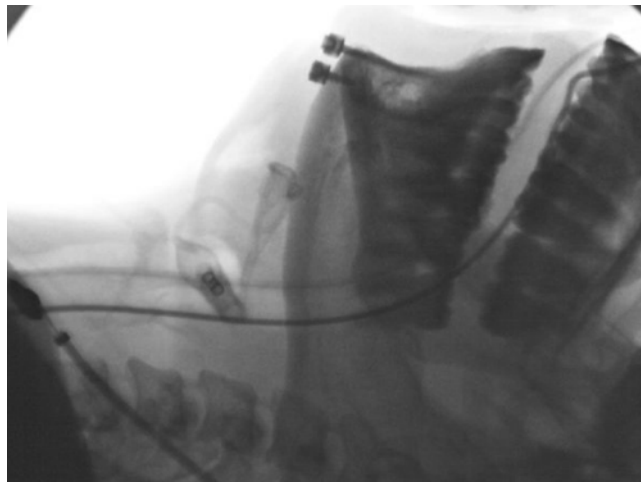
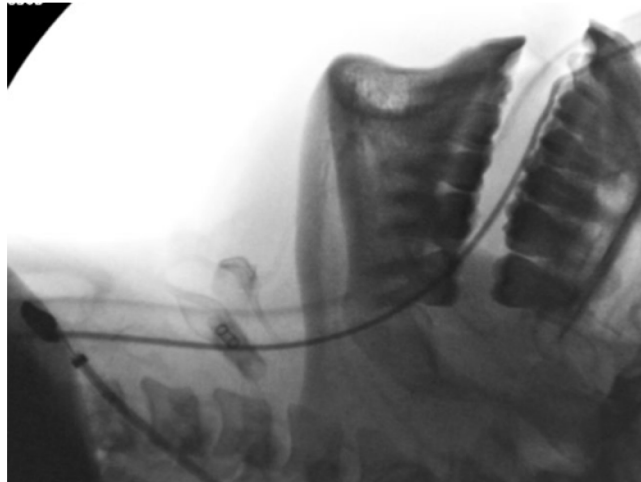
## Patient #3



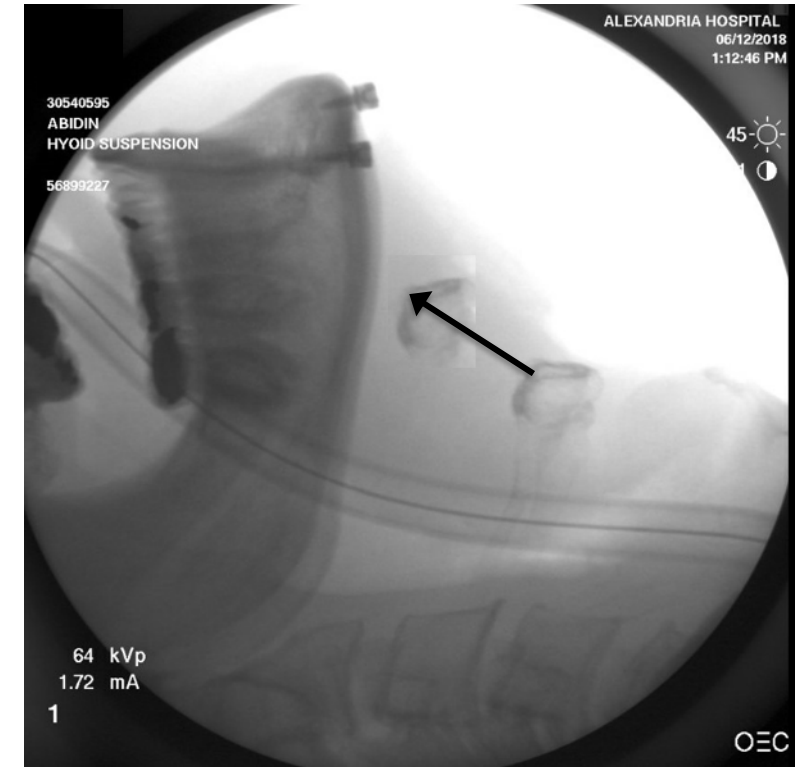
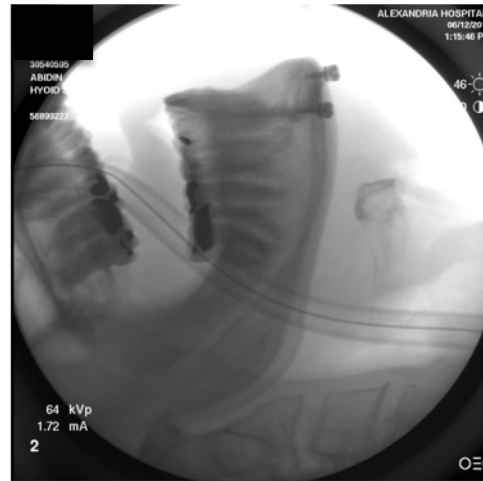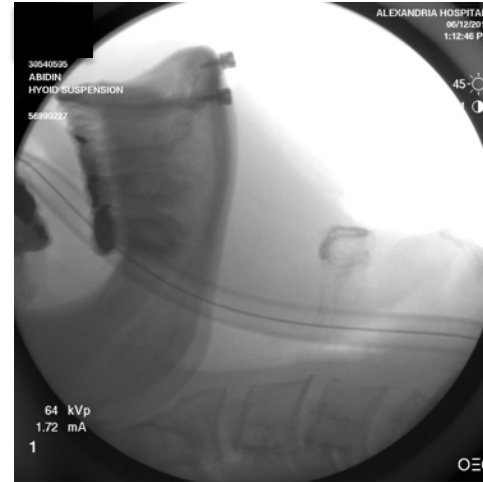
## Patient #4



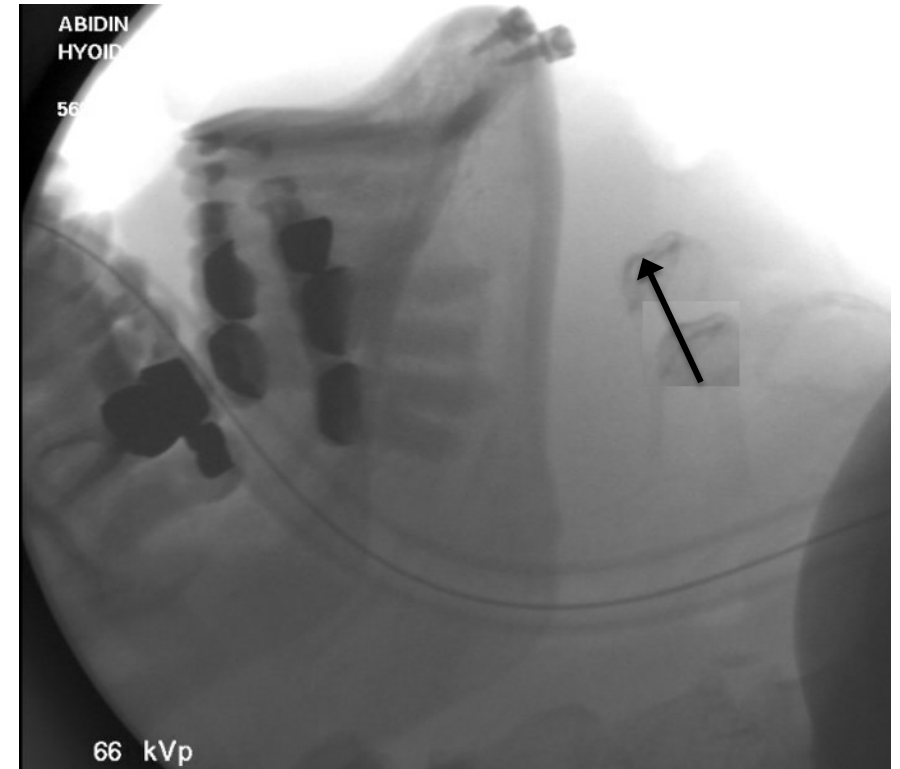
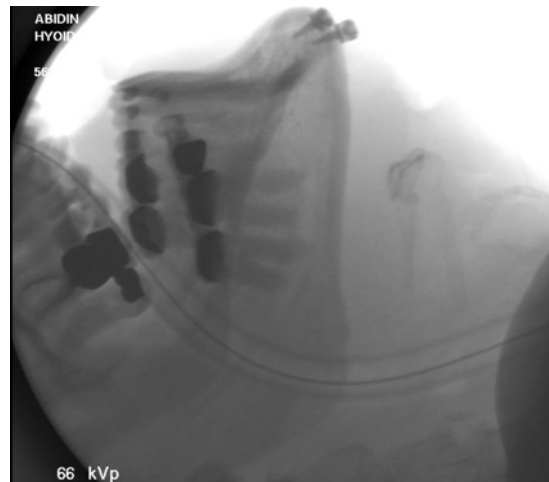
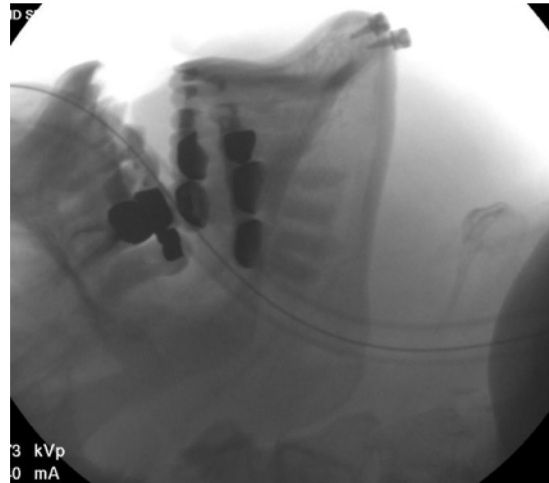
**Patient #5**



## Patient #6

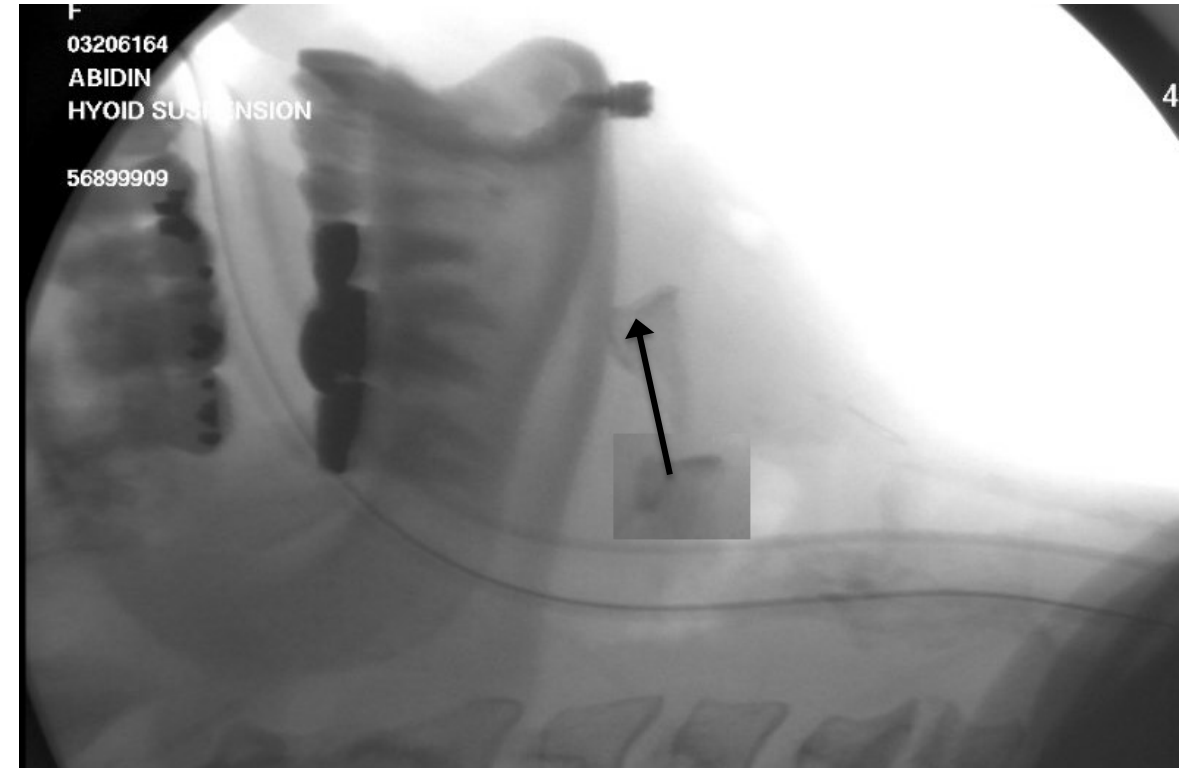
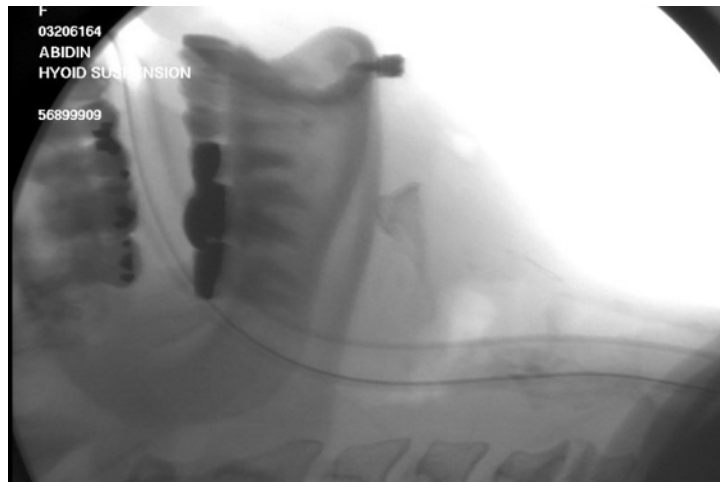
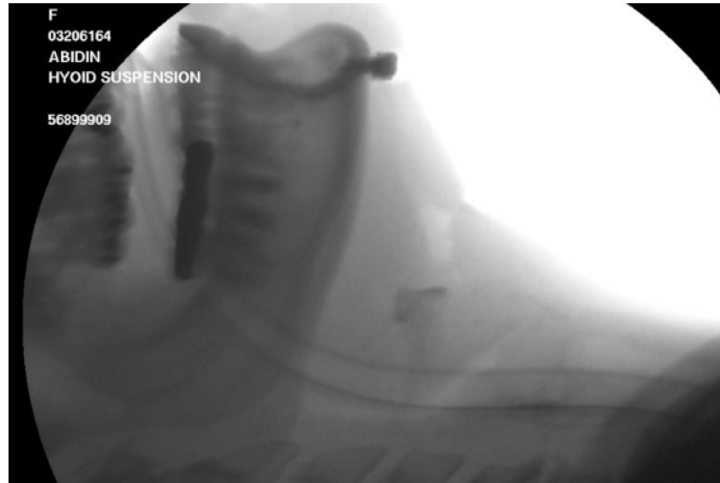

## Patient #7

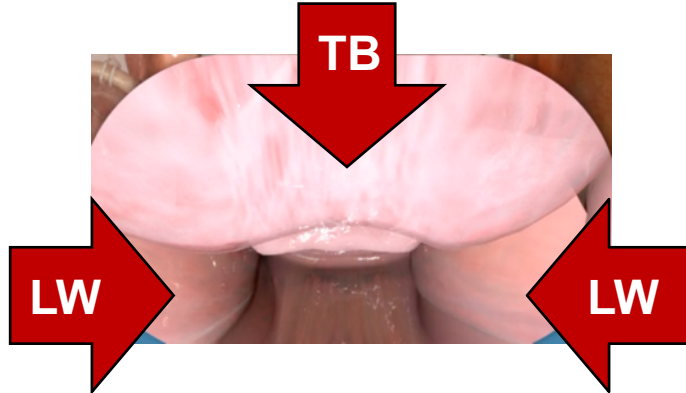
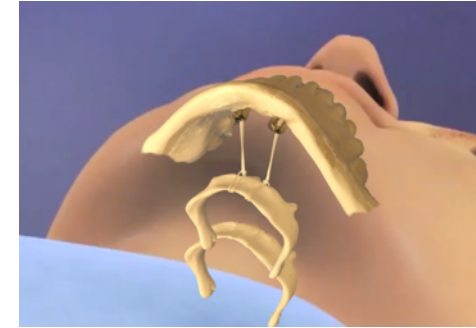
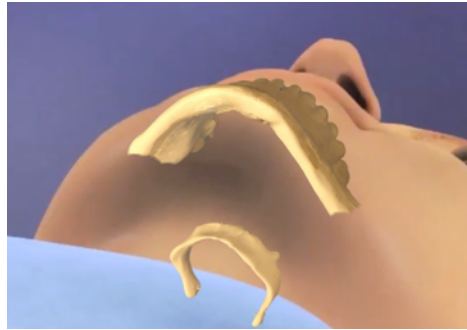




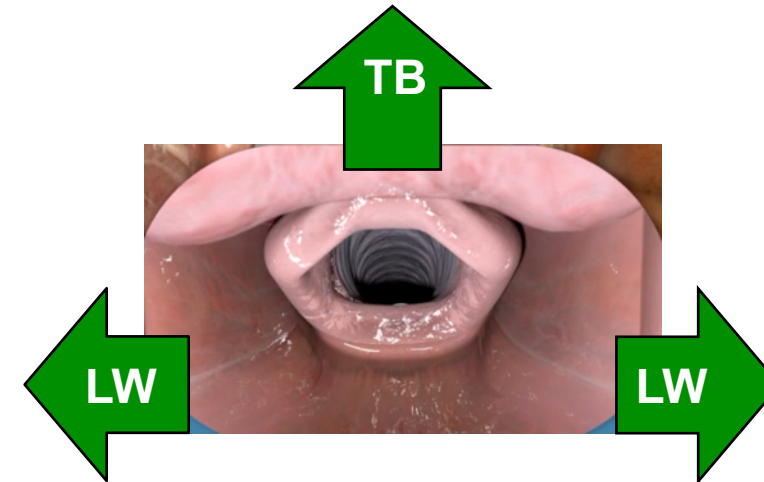
## Patient #8



# Well-controlled Hyoid Suspension to the Mandible: a complete solution



Circumferential  
airway collapse



Circumferential airway  
expansion